

Endoscopic extended transsphenoidal resection of craniopharyngiomas: nuances of neurosurgical technique

ANDREW R. CONGER, M.D., M.S.,¹ JOSHUA LUCAS, M.D.,² GABRIEL ZADA, M.D.,²
THEODORE H. SCHWARTZ, M.D.,³ AND AARON A. COHEN-GADOL, M.D., M.Sc.⁴

¹Department of Neurosurgery, Louisiana State University Health Sciences Center, New Orleans, Louisiana;

²Department of Neurological Surgery, University of Southern California, Los Angeles, California;

³Departments of Neurological Surgery, Otolaryngology, and Neuroscience, Brain and Spine Center, Brain and Mind Research Institute, Weill Cornell Medical College, NewYork-Presbyterian Hospital, New York, New York; and ⁴Department of Neurological Surgery, Indiana University and Goodman Campbell Brain and Spine, Indianapolis, Indiana

Endoscopic approaches to the midline ventral skull base have been extensively developed and refined for resection of cranial base tumors over the past several years. As these techniques have improved, both the degree of resection and complication rates have proven comparable to those for transcranial approaches, while visual outcomes may be better via endoscopic endonasal surgery and hospital stays and recovery times are often shorter. Yet for all of the progress made, the steep learning curve associated with these techniques has hampered more widespread implementation and adoption. The authors address this obstacle by coupling a thorough description of the technical nuances for endoscopic endonasal craniopharyngioma resection with detailed illustrations of the important steps in the operation. Traditionally, transsphenoidal approaches to craniopharyngiomas have been restricted to lesions mostly confined to the sella. However, recently, endoscopic endonasal resections are more frequently employed for extrasellar and purely third ventricle craniopharyngiomas, whose typical retrochiasmatic location makes them ideal candidates for endoscopic transnasal surgery.

The endonasal endoscopic approach offers many advantages, including direct access to the long axis of the tumor, early tumor debulking with minimal manipulation of the optic apparatus, more precise visualization of tumor planes, particularly along the undersurface of the chiasm and the roof of the third ventricle, and a minimal-access corridor that obviates the need for brain retraction. Although much emphasis has been placed on technical tenets of exposure and “how to get there,” this article focuses on nuances of tumor resection “when you are there.” Three operative videos illustrate our discussion of technical tenets.

(<http://thejns.org/doi/abs/10.3171/2014.7.FOCUS14364>)

KEY WORDS • endoscopic • endonasal endoscopic approach • technique • craniopharyngioma • microsurgery

HARVEY Cushing once called craniopharyngiomas the “most forbidding of the intracranial tumors.”^{8,10,13} These uncommon, challenging lesions typically arise from rests of metaplastic adenohypophyseal cells of the pituitary stalk that subsequently exhibit highly variable growth patterns.¹ This locus of origin is surrounded by critical neurovascular structures, ensuring that as a craniopharyngioma grows, it inevitably adheres to and encases some or all of the following structures: the optic nerves and chiasm, pituitary gland and stalk, circle of Willis, brainstem, hypothalamus, third ventricle, and frontal/temporal lobes. As a result, craniopharyngiomas

can be a source of significant neurological morbidity despite their benign histopathology.

Gross-total resection with preservation of neurological function is the ultimate goal in treatment of craniopharyngiomas, resulting in the highest rates of recurrence-free survival and preserved quality of life.^{3,17,30,31} Traditionally, the transsphenoidal approach has been reserved for craniopharyngiomas confined to the sella, whereas lesions originating in or extending to extrasellar locations were approached via the transcranial routes. As endoscopic technology, instrumentation, and relevant anatomical mastery have improved, the indications for transsphenoidal craniopharyngioma surgery have broadened,¹³ and an emerging body of literature suggests that for most craniopharyngiomas, the degree of resection

Abbreviation used in this paper: ICA = internal carotid artery.

via the endonasal endoscopic approach in experienced hands is comparable or superior to those of transcranial routes,^{7,12,18,21,23} but less invasive, potentially leading to improved visual outcome and shorter postoperative hospital stays. Although the increased rate of CSF leakage after transnasal surgery remains a challenge, major improvements over the past decade have been made with widespread adoption of multilayered closure with vascularized reconstruction.^{11,27,29,36}

Craniopharyngiomas originate along the midline skull base, usually ventral to the optic chiasm (Fig. 1) within the retrochiasmatic space and allow a direct unencumbered exposure of their long axis via the endoscopic endonasal approach, which obviates the need for retraction of the brain or optic apparatus, thereby decreasing the risk of retraction-related injury that is often associated with transcranial approaches.^{19,26} Although the benefits of the endoscopic technique for properly selected patients are clear, neurosurgeons have been slow to adopt it because of the steep operator's learning curve.^{20,34,40} To that end, we present this technical descriptive report and detailed illustrations of the technical nuances recommended for endonasal endoscopic resection of craniopharyngiomas.

Preoperative Considerations

Resection of a craniopharyngioma is indicated for lesions causing neurological deficits, pituitary dysfunction,

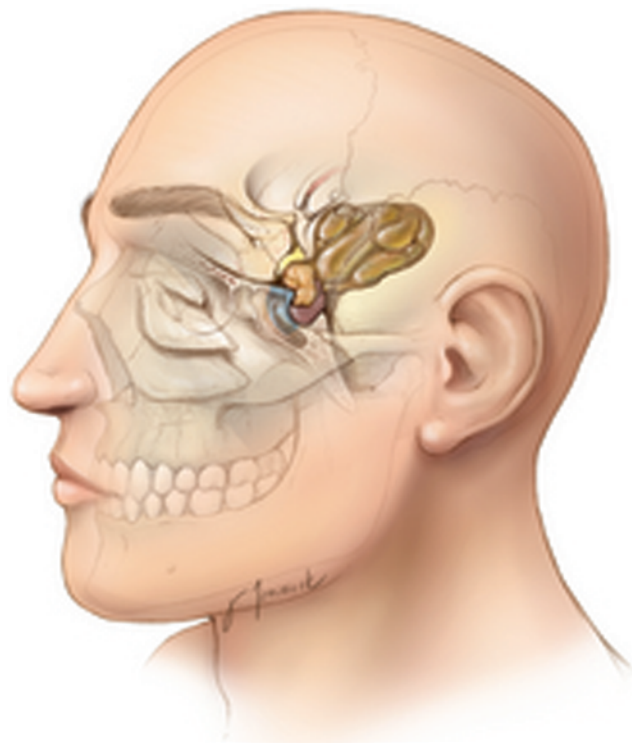


Fig. 1. Location of a large craniopharyngioma in relation to surface landmarks. Note the enhanced working angles along the long axis of the tumor afforded through the transnasal route. Most tumors are retrochiasmatic and ideally exposed through this route as compared with the transcranial route. From *The Neurosurgical Atlas*. Copyright Aaron Cohen-Gadol. Published with permission.

or obstructive hydrocephalus and for those with documented growth on serial imaging. Preoperative evaluation should begin with a thorough history and neurological exam. Evaluation also includes neuroophthalmological testing with special attention to visual fields, endocrinological testing, and thorough interpretation of imaging studies. Neuropsychological evaluation is often helpful for patients with lesions causing mass effect, especially the ones affecting the frontal or medial temporal lobes,¹⁴ but it is not routinely performed at most centers.

Computed tomography is useful for demonstrating calcification and any bony changes caused by the tumor, as well as the degree of aeration and locations of septations in the sphenoid sinus. This is particularly important in children, whose nasal sinuses are often less developed than those of adults, because poorly aerated sinuses may preclude the use of the endoscopic endonasal approach. Magnetic resonance imaging provides excellent detail about the tumor's size, location, associated cysts, and involvement of surrounding neurovascular structures. Cerebral vasculature in relation to the tumor can often be adequately assessed on T2-weighted MRI, but if necessary, angiographic studies can further elucidate the anatomical deformation of the blood vessels involved. Evidence of obstructive hydrocephalus on preoperative imaging is an important consideration, and if it is symptomatic or worsening, an external ventricular drain is placed preoperatively. Usually the patient is successfully weaned after tumor resection. Hypothalamic involvement by the tumor usually is best seen on coronal FLAIR sequences.

Iatrogenic hypothalamic injury often results from overly aggressive resection of a tumor adherent to the hypothalamus. Injury to the hypothalamus can cause hyperphagia and subsequently lead to morbid obesity as well as cognitive issues and is of particular concern in children. Before any operation for craniopharyngiomas, a plan for a subtotal versus total resection should be made based on the degree of hypothalamic and infundibular involvement. A safe subtotal resection is favored over gross-total resection with hypothalamic injury. Details of potential intraoperative decision making should be thoroughly discussed with the patient and family preoperatively, especially as they pertain to sacrificing the pituitary stalk to facilitate gross-total tumor resection and subsequent expectations for panhypopituitarism.

The endoscopic endonasal approach is best suited for sellar and suprasellar craniopharyngiomas without significant lateral extension beyond the carotid bifurcation, vascular encasement, or multicompartiment location. Relative contraindications to the endoscopic approach for some surgeons are large, solid tumors, tumors with significant calcification, and tumors with unusual anatomy such as a very narrow sella with minimal distance between the carotid arteries. We have employed the endoscopic endonasal technique for most of our patients with craniopharyngiomas, including those with purely third ventricle lesions, with the exception of those harboring tumors with significant extension lateral to the carotid bifurcation.

Craniopharyngiomas have been classified based on several criteria, including their relationship to the optic

Resection of craniopharyngiomas

chiasm,¹⁶ diaphragma sellae,⁴² third ventricle,⁴¹ and infundibulum.¹⁹ For suprasellar lesions approached via the endoscopic endonasal corridor, the infundibular classification system is most appropriate because it facilitates surgical planning and intraoperative decision making. The location of the craniopharyngioma in relation to the infundibulum is evaluated on MRI. Type I lesions are preinfundibular and located anterior to the pituitary stalk. As they grow, they tend to displace the optic chiasm posteriorly and superiorly and often involve the anterior communicating artery complex. Type II lesions are transinfundibular, infiltrating the pituitary stalk and growing along its axis. These lesions often extend superiorly into the third ventricle and typically require sectioning of the pituitary stalk for their gross-total resection. Type III lesions are retroinfundibular, located posterior to the pituitary stalk. These lesions can grow superiorly into the third ventricle (Subtype IIIa) or posteriorly and inferiorly into the prepontine and interpeduncular cisterns (Subtype IIIb). Type IV lesions are purely intraventricular.¹⁹

Patient Position

Following induction of general anesthesia, we routinely place a lumbar drain and then clamp the drain for the duration of the operation. The drain can be used for administration of intrathecal fluorescein if desired.³⁷ The patient's head is placed either on a donut gel rest or in rigid pin fixation with the neck slightly extended and the head raised just above the level of the heart. Frameless stereotactic neuronavigation is registered using preoperative CT and MRI. A fascia lata donor site is prepared in anticipation of cranial base reconstruction. Routine nasal mucosal preparation is performed; preoperative antibiotics and a stress dose of methylprednisolone are administered.

Approach

The operation, which is a collaborative effort between the neurosurgeon and an otolaryngologist, begins with the elevation of a vascularized nasoseptal flap.¹⁵ The mucosal side of the flap is mobilized into the nasopharynx until tumor resection is complete, taking care to prevent twisting of the pedicle and resultant ischemia. The operation proceeds with a binostril technique in which one surgeon works bimanually while another drives the endoscope, using dynamic visualization to facilitate 3D perception of the surgical field. The use of an endoscope holder is an alternative technique.

The initial phase of the approach is performed by the otolaryngologist and consists of lateral mobilization of the middle and inferior turbinates bilaterally, identifying the sphenoid ostia, performing a posterior septectomy, creating a wide sphenoidotomy, removing the sphenoid mucosa, performing partial posterior ethmoidectomies, and drilling the bony septations within the sphenoid sinus. The middle turbinate can be removed on one side to accommodate the endoscope to prevent its interference with the manipulation of instruments,³² but often the turbinates can be preserved. During later steps of the exposure and subsequent resection, use of a 30° angled endoscope may be preferable so the tip of the endoscope can

be moved out of the working zone of surgical instruments while maintaining adequate visualization. This maneuver also allows the endoscope to provide better superior and lateral views without a frequent need to exchange 0° and 30° endoscopes.^{22,26}

A wide sphenoidotomy is important for the remainder of the operation as it allows greater degrees of freedom for passage and manipulation of instruments in the deep operative field above the chiasm and minimizes the potential for instrument/endoscope collision. If both opticocarotid recesses cannot be seen with a 0° scope, the lateral exposure is inadequate. The lateral aspect of the surgical corridor should be limited by the nasal turbinates rather than remnants of the anterior sphenoid wall. Performing posterior ethmoidectomies fully exposes the planum sphenoidale, and although the lesion may not extend to this level, this maneuver expands the operative corridor, widens working angles, and prevents overhanging bone from impeding visualization and manipulation of instruments. Complete removal of the sphenoid mucosa prevents formation of a postoperative mucocele, reveals important bony landmarks necessary for subsequent steps in the procedure, and also provides the necessary bony substrate for adhesion of the pedicled nasoseptal flap.

The medial opticocarotid recess is an important landmark as it represents the ventral aspect of a pneumatized middle clinoid process. It marks the medial aspects of both the parasellar carotid canal and the cavernous sinus, the lateral edge of the sella, and the inferomedial aspect of the optic nerve. The medial opticocarotid recess is the most lateral extent of the tuberculum sellae, and removal of bone over this landmark widens intradural exposure and allows the surgeon to work from normal anatomy toward pathological anatomy by early identification of the optic nerves and paraclinoid internal carotid artery (ICA), followed by visualization of the opticocarotid cistern and supraclinoid ICA. In this manner, chiasmatic perforators and the superior hypophyseal arteries are more likely to be identified and protected.^{5,9,19} Unfortunately, the medial opticocarotid recess is not always visible, so the lateral opticocarotid recess and bony prominences over the carotid artery can be used to localize the medial opticocarotid recess. The sella is usually easily identified between the bilateral carotid artery prominences. The clival recess is visible inferior to the sella. If the sphenoid sinus is not well pneumatized, as in young children, these landmarks may be difficult to recognize, necessitating sole reliance on navigation and careful thinning of the bone until the landmarks can be reliably distinguished.²

A high-speed diamond-bit drill (or ultrasonic curette) is used to remove bone over the sella turcica, tuberculum sellae, and posterior portion of the planum sphenoidale. Bone removal extends laterally to the medial opticocarotid recess (Fig. 2). The bone is initially thinned with the drill and then removed with a Kerrison rongeur. Copious irrigation is used when drilling over the medial opticocarotid recess to prevent thermal injury to the optic nerve. Venous bleeding is often encountered upon removal of bone in this area, but even vigorous venous bleeding is usually easily controlled with gelfoam packing and gentle pressure.

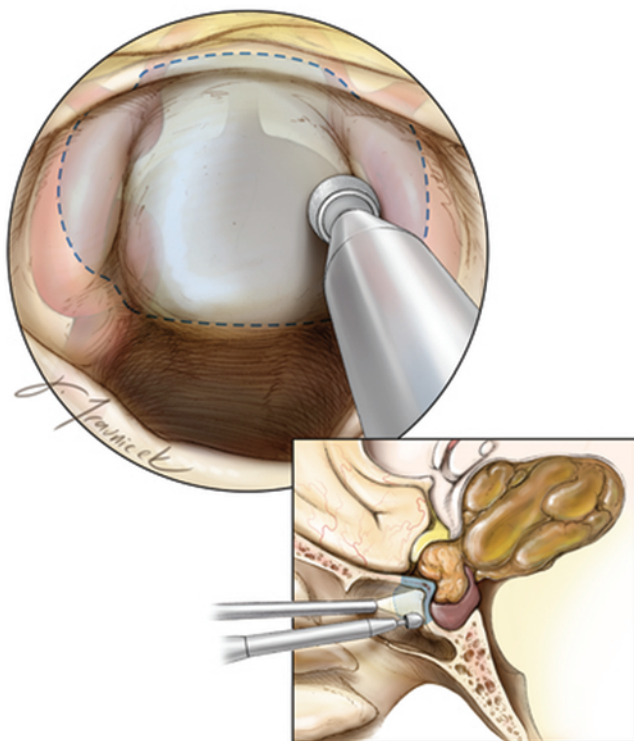


FIG. 2. Exposure of bony landmarks along the posterior sphenoid wall. Bone is removed laterally to the level of the medial opticocarotid recesses, inferiorly about halfway down to the anterior sellar wall to protect the pituitary gland, and superiorly to the level of the posterior aspect of the planum sphenoidale. The **inset** shows the sagittal view of the craniopharyngioma. Note the significant posterior extension of the tumor, which does not preclude the use of endoscopic surgery. From *The Neurosurgical Atlas*. Copyright Aaron Cohen-Gadol. Published with permission.

The extent of bony exposure in the sagittal plane is determined by the size and location of the tumor along the same plane and can be facilitated intraoperatively using neuronavigation. Tumors confined to the sella require removal of the anterior sellar wall, whereas preinfundibular tumors within the suprasellar cistern require more bony removal over the tuberculum sellae and planum sphenoidale and less removal of the inferior/anterior sellar wall.¹⁹ However, it is recommended to open above and below the superior intercavernous sinus to control and resect this vascular structure to open the diaphragma sellae, which lies just behind this sinus. Transfundibular tumors often extend superiorly into the anterior third ventricle and their exposure requires excision of additional bone over the anterior sella to accommodate the steeper working angles required to reach the superior ventricular extent of these tumors.¹⁹ Retroinfundibular tumors necessitate removal of the sellar floor along the inferior intercavernous sinus and occasionally the posterior clinoid processes and dorsum sellae.¹⁹ This extensive bone removal allows exposure and resection of tumor extending from the infundibulum into the prepon-tine and interpeduncular cisterns, as well as lateral transposition of the pituitary gland as needed. Alternatively, an “above and below” approach can be performed to reach both above and behind the sella as needed.³⁹

These tumor type distinctions mentioned above are not absolute, as most craniopharyngiomas occupy more than one of these anatomical compartments.¹⁹ The superior extent of bony opening along the planum sphenoidale does not need to expand since most dissection is carried out beneath the chiasm. However, if the tumor extends markedly above the chiasm, requiring a translamina terminalis approach, additional bone resection along the planum may be indicated. Following adequate bony removal as confirmed by navigation, the superior intercavernous sinus is coagulated and the dura is opened in a cruciate fashion (Fig. 3). The dural edges are cauterized and shrunk to increase visualization. It is also possible to excise the dural edges using kerrison rongeurs to expand the operative corridor. Prior to dural opening, micro-Doppler ultrasonography is routinely used to avoid injury to the ICA, especially as its proximal supraclinoid portion courses medially.

Tumor Resection

Resection of craniopharyngiomas follows general principles of microsurgical tumor resection, including internal debulking, extracapsular dissection, protection of neurovascular structures (including parasellar perforating arteries), and intraoperative decision making pertaining to leaving residual tumor if excessive dissection is likely to result in neurological morbidity.

Upon opening the dura, preinfundibular tumors are immediately visible. The tumor often has a thin layer of arachnoid covering, which must be opened sharply. It is important to try to identify the stalk and the superior hy-

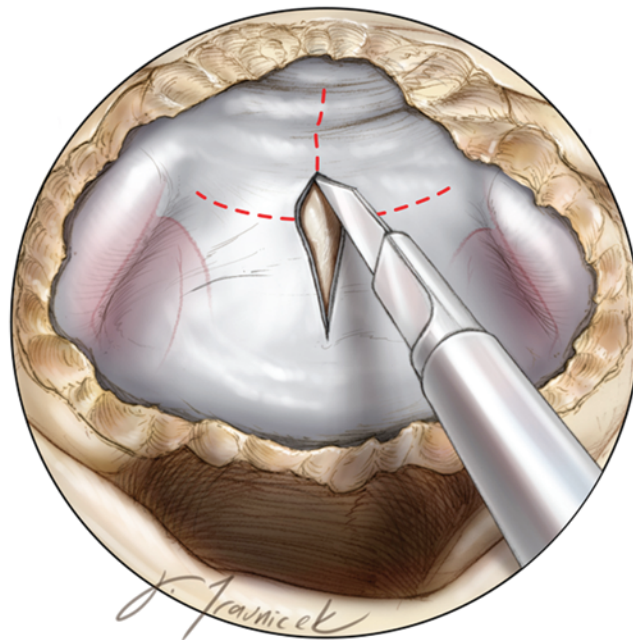


FIG. 3. Please note that we prefer to remove bone laterally over the carotid arteries to allow more working angles laterally by gently mobilizing these vascular structures. The dura is opened over the sella in a cruciate fashion. The dural incisions may be guided by ultrasonography to avoid injury to the ICAs. From *The Neurosurgical Atlas*. Copyright Aaron Cohen-Gadol. Published with permission.

Resection of craniopharyngiomas

pophyseal arteries as early as possible to facilitate their preservation for as long as possible until it is determined that gross-total resection will necessitate the sacrifice of pituitary function. The capsule is then incised, allowing drainage of cystic tumors or internal debulking of solid tumors using a ring curette (Fig. 4). This maneuver is critical in facilitating the next steps of tumor mobilization and should be performed very carefully for tumors with significant extension anterior to the chiasm because these tumors often involve the A_2 segments of the anterior cerebral arteries, the A_1 – A_2 junction, anterior communicating artery, and/or recurrent arteries of Huebner.

Once the tumor has been debulked, the surgeon may sharply dissect its capsule from the underside of the chiasm while meticulously preserving the perforators supplying the chiasm (Fig. 5). Injury to such perforators is a major cause of visual deterioration following craniopharyngioma surgery. The capsule is subsequently opened more widely and the tumor is further debulked (Fig. 6).

The capsule is then mobilized and dissected medially with enough traction to stretch the arachnoid adhesions without tearing small blood vessels (Fig. 7). These arachnoid adhesions are sharply incised and the opticocarotid cistern is entered, after which the ICA is traced superiorly while carefully preserving the superior hypophyseal arteries and other small perforating vessels. In this manner, dissection proceeds along the lateral aspect of the tumor on each side.

Circumferential dissection continues and the tumor is further dissected from the inferior aspect of the chiasm

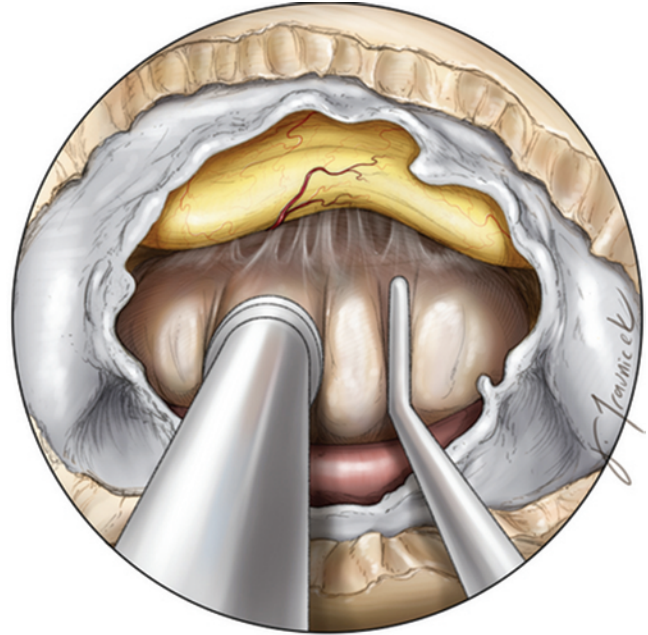


FIG. 5. After debulking, the capsule is dissected from the underside of the optic chiasm. Care is taken to prevent injury to small en passage vessels in this area. From *The Neurosurgical Atlas*. Copyright Aaron Cohen-Gadol. Published with permission.

(Fig. 8). As dissection proceeds posteriorly, the tumor is untethered from the floor of the third ventricle (Fig. 9). This maneuver is performed with great care, especially in cases in which the tumor has significant third ventricular involvement. In many cases, the floor of the third

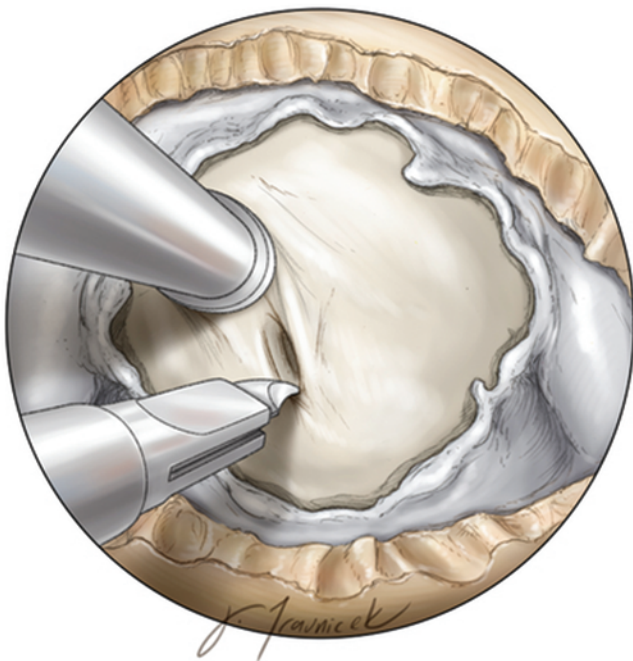

FIG. 4. Upon opening the dura, the only visible structures may be the arachnoid and tumor capsule. The operator should remain patient and decompress the tumor, as this maneuver will mobilize the mass and allow identification of surrounding cerebrovascular structures. Overzealous bony removal may lead to an increased risk of postoperative CSF leakage. From *The Neurosurgical Atlas*. Copyright Aaron Cohen-Gadol. Published with permission.

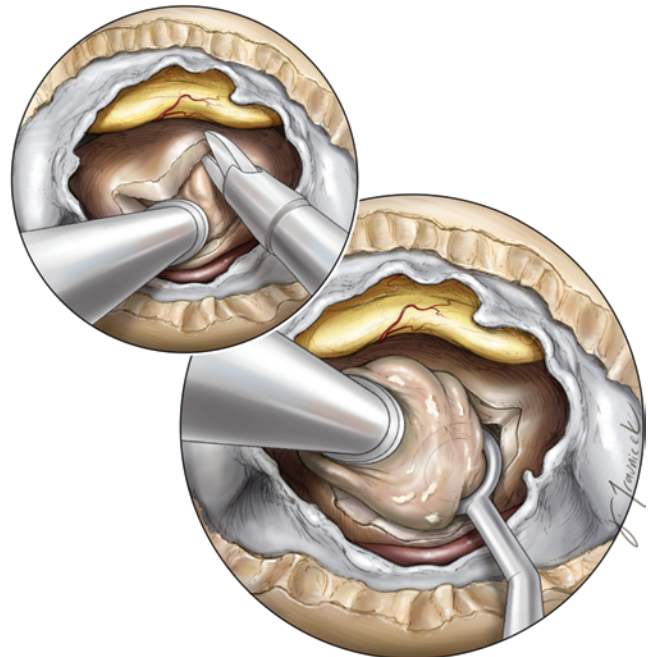

FIG. 6. Once the tumor is partially freed from the chiasm, the capsule is opened more widely and further internal tumor debulking is performed. Ring curettes are used to excise the solid calcified portions of the tumor and drain the associated cysts. From *The Neurosurgical Atlas*. Copyright Aaron Cohen-Gadol. Published with permission.

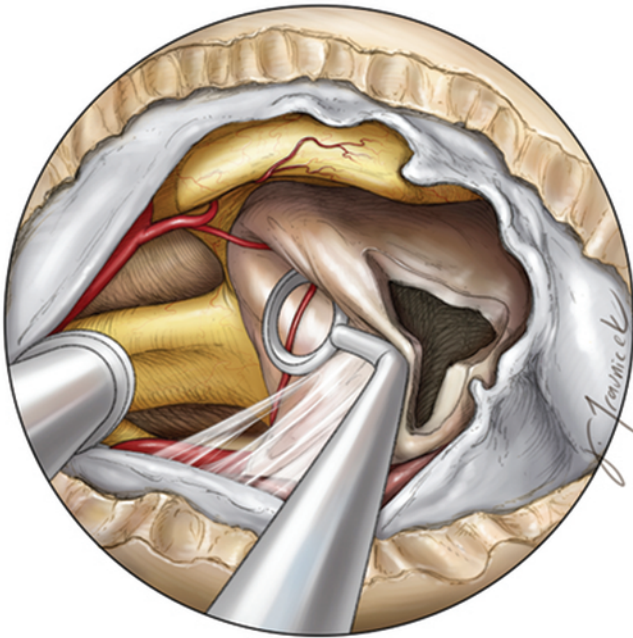


FIG. 7. The opticocarotid cistern is entered as the tumor is gently mobilized medially. The arachnoid adhesions are stretched and then sharply divided. Dissection proceeds along the ICA on each side of the tumor. The branches of the superior hypophyseal arteries to the tumor and chiasm are recognized and the latter are preserved. From *The Neurosurgical Atlas*. Copyright Aaron Cohen-Gadol. Published with permission.

ventricle is not intact and dissection is carried up into the ventricle, and the tumor is removed from the lateral and superior walls. If necessary, some portion of tumor is left behind to prevent traction injury to the hypothalamic nu-

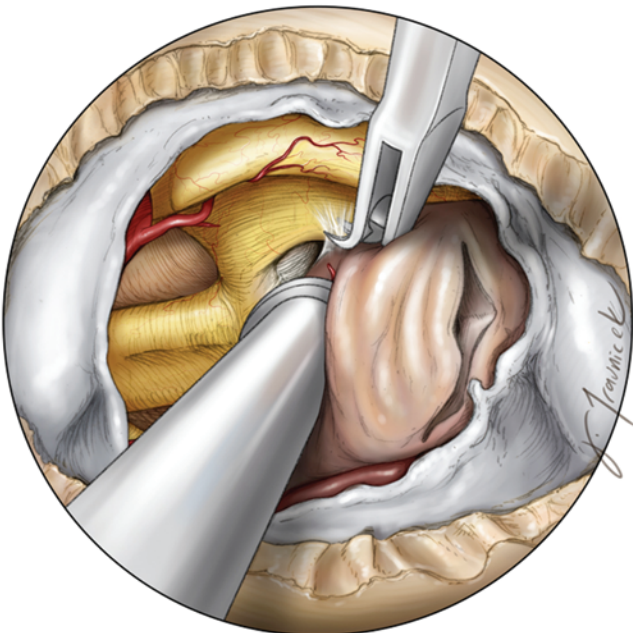


FIG. 8. Sharp dissection continues circumferentially around the tumor capsule, which is released from the inferior aspect of the chiasm. From *The Neurosurgical Atlas*. Copyright Aaron Cohen-Gadol. Published with permission.

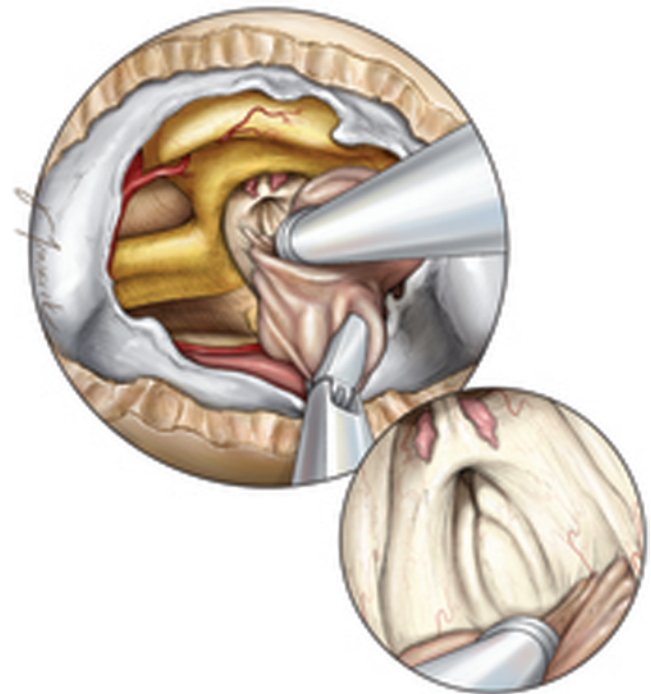


FIG. 9. Dissection proceeds posteriorly and the tumor is removed from the walls of the third ventricle. Great care is taken to avoid aggressive traction on the tumor in this area as this may cause injury to the hypothalamus. Angled endoscopes allow careful inspection of the ventricular walls and hypothalamus (*inset*). From *The Neurosurgical Atlas*. Copyright Aaron Cohen-Gadol. Published with permission.

clei. One can remove the third ventricular portion of the tumor after the rest of the tumor is removed. This strategy provides more expanded visualization of the operative corridor during dissection of tumor from the walls of the hypothalamus.

Once the tumor has been dissected from the ventricle, the surgeon's attention turns to the inferior pole of the tumor, which is freed from the diaphragma sellae and pituitary gland. If the tumor extends down into the sella, the diaphragma must be transected. The pituitary stalk is then evaluated (Fig. 10). Management of the pituitary stalk requires a judicious intraoperative inspection regarding its preservation or sacrifice. Ideally, every attempt is made to preserve the pituitary stalk. However, if there is the potential for gross-total resection, we recommend transecting the stalk to achieve a complete gross-total resection. Preoperative pituitary function also influences this decision. Pituitary function frequently declines postoperatively, so poor preoperative endocrine function may further justify the decision to section the pituitary stalk.^{26,35} This philosophy is particularly relevant for the transinfundibular type of craniopharyngioma in which the pituitary stalk is often infiltrated with tumor.¹⁹ However, keep in mind that it is not uncommon for the surgeon to leave some portion of tumor behind to try to preserve pituitary function only to find out postoperatively that the trauma of surgery has already damaged pituitary function, and one is left with the unfortunate situation of a patient who did not intentionally undergo gross-total resection and is suffering from panhypopituitarism. Likewise, postoperative radia-

Resection of craniopharyngiomas

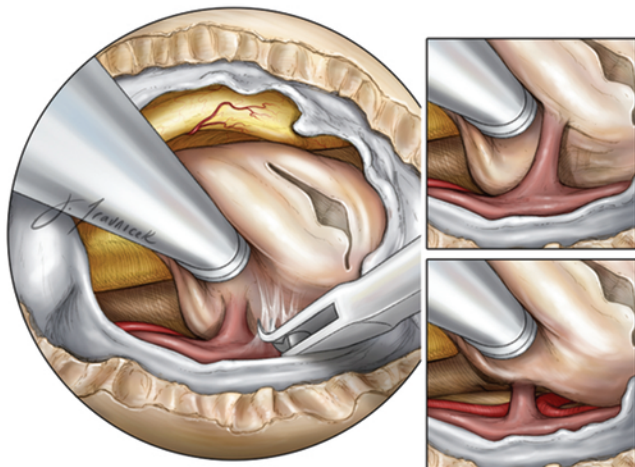


FIG. 10. The tumor is sharply dissected from the diaphragma sellae and the pituitary stalk is evaluated (*insets*). From *The Neurosurgical Atlas*. Copyright Aaron Cohen-Gadol. Published with permission.

tion therapy often results in diminished pituitary function and is not always effective at controlling cyst growth. For these reasons, it is often preferable to definitively complete a gross-total resection and resect the stalk and plan on postoperative hormonal replacement therapy.

Following management of the pituitary stalk, the tumor is often still tethered posteriorly to the mammillary bodies or basilar artery and its branches. It is important to resist the temptation to pull on the tumor at this stage. The tumor should be sharply and patiently dissected from the mammillary bodies, optic tracts, membrane of Liliquist, posterior cerebral arteries, posterior communicating arteries, and thalamoperforators (Fig. 11), and then

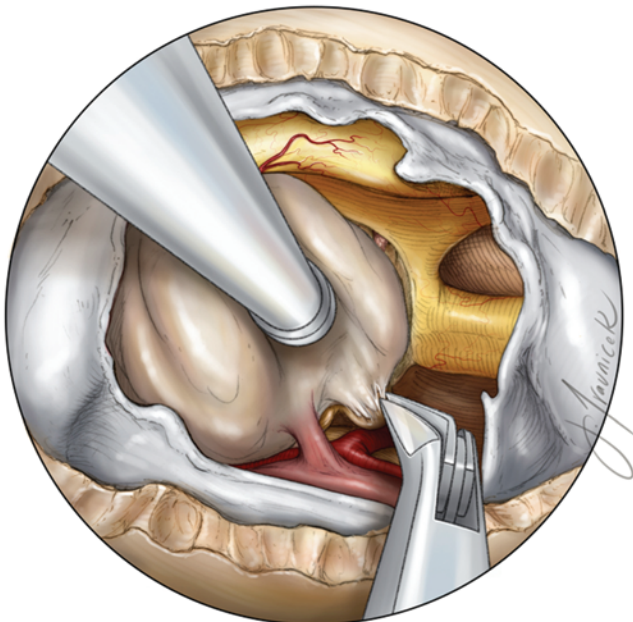


FIG. 11. The tumor is sharply dissected from the mammillary bodies. Indiscriminate traction of the tumor is avoided. The tumor is dissected away from the optic tracts and branches of the basilar artery. From *The Neurosurgical Atlas*. Copyright Aaron Cohen-Gadol. Published with permission.

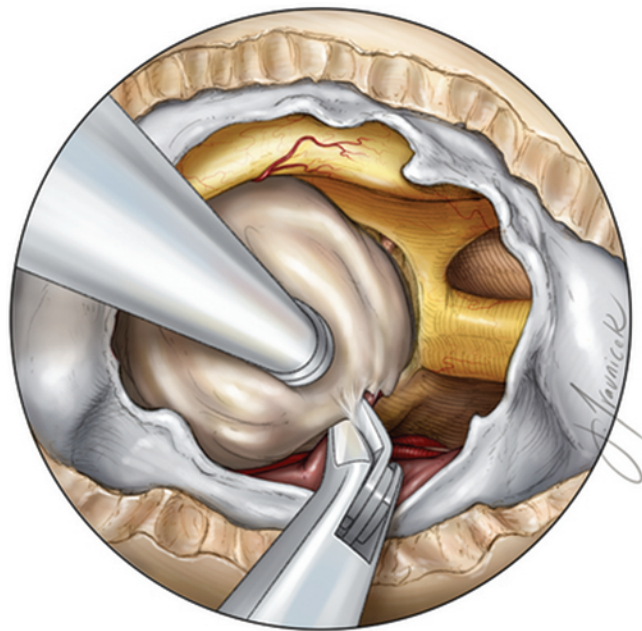


FIG. 12. The tumor is sharply dissected off of the pituitary stalk using angled microscissors. From *The Neurosurgical Atlas*. Copyright Aaron Cohen-Gadol. Published with permission.

finally sharply excised from the pituitary stalk (Fig. 12). The resection cavity is then thoroughly explored with 30°, 45°, and 70° endoscopes, assessing for bleeding and examining the third ventricle for residual tumor (Fig. 13). Lateral extensions of the tumor are dissected using a 45° endoscope. The use of angled endoscopes and dissecting instruments has radically expanded the realm of endoscopic transnasal surgery and associated operative

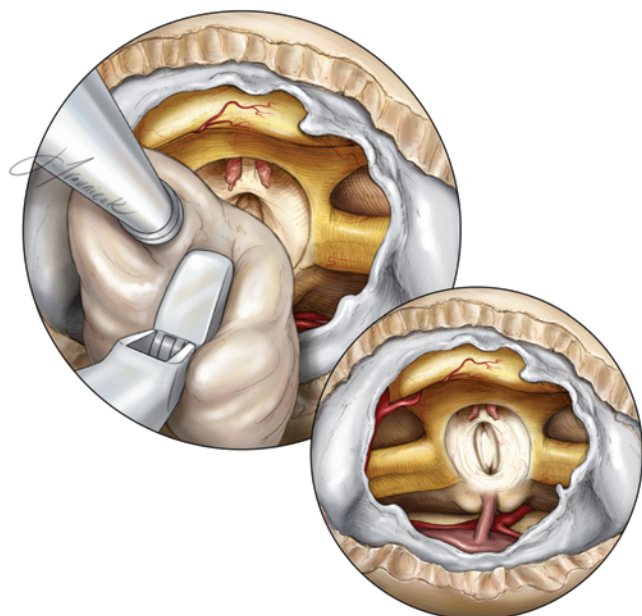


FIG. 13. The tumor is removed from the resection cavity, and the third ventricle is assessed for bleeding and residual tumor. Note the view of the basilar apex and posterior cerebral arteries. From *The Neurosurgical Atlas*. Copyright Aaron Cohen-Gadol. Published with permission.

corridors for removal of large craniopharyngiomas previously considered inoperable through this route. Copious irrigation is recommended following craniopharyngioma resection, as the tumor contents can be caustic to normal neurological structures and incite chemical meningitis.

Closure

Meticulous closure is important for minimizing the risk of postoperative CSF leakage, the most prevalent complication of endoscopic surgery. A variety of reconstruction methods and graft materials are available to the surgeon. In the gasket seal method, a piece of harvested fascia lata or allograft dural substitute is placed over the bony defect so that its dimensions exceed that of the defect by at least 1 cm circumferentially. A Porex rigid implant (Stryker) cut to fit the opening is then placed over the fascia lata and counter-sunk within the bony defect. This technique creates a gasket seal similar to that described by Leng and others.^{11,24} An alternative approach involves a multilayer fascia lata reconstruction used with the layers in apposition to one another, with the first as a dural inlay and the second as a larger dural overlay, thereby potentially obviating the need for a rigid buttress.

The nasoseptal flap is then placed over the preferred method of initial closure so that the flap is in direct apposition to the surrounding bony skull base and is subsequently held in place with DuraSeal (Covidien) or fibrin glue or an inflated Foley balloon.²² This method of closure has proven effective, with reported CSF leak rates of less than 5%¹¹ and even as low as 0%.^{29,36} Bilateral nasoseptal flaps can also be used for larger skull base defects.³³ Floseal (Baxter) is administered to stop bleeding from mucosa, and we insert a gelfoam sponge followed by nasal tampons to buttress the closure and limit postoperative nasal discharge. After surgery, the patient is taken to the intensive care unit, where lumbar drainage and stress-dose steroids are continued for 24 hours, after which the drain is removed and the patient is mobilized. When to start lumbar drainage is controversial. Although some surgeons delay initiation of lumbar drainage for 4–6 hours following the procedure so as to avoid overdrainage of CSF, others keep the drain open right away during extubation and transport so that increases in intraabdominal pressure are less likely to dislodge the closure construct.

The details of the surgical technique are shown in Videos 1–3.

VIDEO 1. Endoscopic tumor resection. Copyright Aaron Cohen-Gadol. Published with permission. Click here to view with Media Player. Click here to view with Quicktime.

VIDEO 2. Endoscopic tumor resection. Copyright Gabriel Zada. Published with permission. Click here to view with Media Player. Click here to view with Quicktime.

VIDEO 3. Endoscopic tumor resection. Copyright Theodore Schwartz. Published with permission. Click here to view with Media Player. Click here to view with Quicktime.

Complications

Surgical complications of endoscopic endonasal craniopharyngioma resection include neurological deficits as

a result of direct neural tissue trauma or vascular compromise, pituitary hormonal dysfunction as a result of injury to the pituitary stalk or hypothalamus, and cognitive and psychological abnormalities as a result of injury to the frontal/temporal lobes or hypothalamus. Cerebrospinal fluid leakage and sinonasal morbidity are the most common approach-specific complications. Cerebrospinal fluid leakage has been a significant problem since the extended endoscopic endonasal approach was first introduced, but as closure techniques have improved (in particular with widespread adoption of nasoseptal flap reconstruction), CSF leak rates have dropped as low as 0% in some recent reports.^{27,36} In most series, the rate of postoperative CSF leakage remains in the 10%–15% range.^{4,6,7,12,25,31,43} Sinonasal quality of life is decreased in the postoperative period, but this appears to be transient as it returns to baseline over time.^{28,43}

The most common postoperative complication is diabetes insipidus. Diabetes insipidus often exists preoperatively and worsens postoperatively in 42%–64% of patients who undergo this procedure, but there is often improvement in some patients over time.^{4,6,25} Dysregulation of anterior pituitary hormones is also common, with 28%–46% of patients exhibiting postoperative pituitary axis dysfunction.^{4,6,25} Postoperative visual worsening occurs in about 2%–7% of patients.^{4,6,25} Hyperphagia due to hypothalamic injury, which may lead to morbid obesity, is a well-described complication following craniopharyngioma resection, especially in children.³⁸ Although in adults the rate of occurrence of this complication is not well quantified, according to Leng et al.²⁵ the frequency after endoscopic endonasal resection is comparable to that following microsurgical resection. Careful monitoring of fluid output and frequent serum sodium evaluations are critical during the immediate postoperative period because in some patients serum sodium levels may rapidly escalate within a dangerous range due to acute development of diabetes insipidus.

Conclusions

The endoscopic endonasal approach is not only a reasonable option for resection of properly selected craniopharyngiomas, but it may also provide results that are superior to those obtained with transcranial approaches with respect to extent of resection and visual improvement without the morbidity related to brain retraction. As the incidence of approach-specific complications such as CSF leaks and sinonasal morbidity continues to decrease, it is increasingly in our patients' best interests to consider using this approach for appropriately selected lesions. Although the learning curve continues to be a relative obstacle to the implementation of endoscopic endonasal methods in many neurosurgical practices, we hope this report will help neurosurgeons who are interested in employing these techniques.

Disclosure

Dr. Schwartz reports owning stock in Visionsense, consulting for Karl Storz, and receiving NIH support of non-study-related clinical or research effort.

Resection of craniopharyngiomas

Author contributions to the study and manuscript preparation include the following. Conception and design: all authors. Acquisition of data: all authors. Analysis and interpretation of data: all authors. Drafting the article: all authors. Critically revising the article: all authors. Reviewed submitted version of manuscript: all authors. Approved the final version of the manuscript on behalf of all authors: Cohen-Gadol.

References

- Asa SL, Kovacs K, Bilbao JM: The pars tuberalis of the human pituitary. A histologic, immunohistochemical, ultrastructural and immunoelectron microscopic analysis. **Virchows Arch A Pathol Anat Histopathol** 399:49–59, 1983
- Banu MA, Guerrero-Maldonado A, McCrea HJ, Garcia-Navarro V, Souweidane MM, Anand VK, et al: Impact of skull base development on endonasal endoscopic surgical corridors. Clinical article. **J Neurosurg Pediatr** 13:155–169, 2014
- Baskin DS, Wilson CB: Surgical management of craniopharyngiomas. A review of 74 cases. **J Neurosurg** 65:22–27, 1986
- Campbell PG, McGettigan B, Luginbuhl A, Yadla S, Rosen M, Evans JJ: Endocrinological and ophthalmological consequences of an initial endonasal endoscopic approach for resection of craniopharyngiomas. **Neurosurg Focus** 28(4):E8, 2010
- Cavallo LM, de Divitiis O, Aydin S, Messina A, Esposito F, Iaconetta G, et al: Extended endoscopic endonasal transsphenoidal approach to the suprasellar area: anatomic considerations—part 1. **Neurosurgery** 62 (6 Suppl 3):1202–1212, 2008
- Cavallo LM, Frank G, Cappabianca P, Solari D, Mazzatenta D, Villa A, et al: The endoscopic endonasal approach for the management of craniopharyngiomas: a series of 103 patients. Clinical article. **J Neurosurg** 121:100–113, 2014
- Cavallo LM, Prevedello DM, Solari D, Gardner PA, Esposito F, Snyderman CH, et al: Extended endoscopic endonasal transsphenoidal approach for residual or recurrent craniopharyngiomas. Clinical article. **J Neurosurg** 111:578–589, 2009
- Cushing H: **Intracranial Tumours. Notes upon a Series of Two-Thousand Verified Cases with Surgical-Mortality Percentages Pertaining Thereto.** Springfield, IL: Charles C Thomas, 1932
- de Divitiis E, Cavallo LM, Cappabianca P, Esposito F: Extended endoscopic endonasal transsphenoidal approach for the removal of suprasellar tumors: Part 2. **Neurosurgery** 60:46–59, 2007
- DiPatri AJ Jr, Prabhu V: A history of the treatment of craniopharyngiomas. **Childs Nerv Syst** 21:606–621, 2005
- Garcia-Navarro V, Anand VK, Schwartz TH: Gasket seal closure for extended endonasal endoscopic skull base surgery: efficacy in a large case series. **World Neurosurg** 80:563–568, 2013
- Gardner PA, Kassam AB, Snyderman CH, Carrau RL, Mintz AH, Grahovac S, et al: Outcomes following endoscopic, expanded endonasal resection of suprasellar craniopharyngiomas: a case series. **J Neurosurg** 109:6–16, 2008
- Gardner PA, Prevedello DM, Kassam AB, Snyderman CH, Carrau RL, Mintz AH: The evolution of the endonasal approach for craniopharyngiomas. Historical vignette. **J Neurosurg** 108:1043–1047, 2008
- Gottfried ON, Couldwell WT: Craniopharyngiomas, in Bernstein M, Berger MS (eds): **Neuro-Oncology. The Essentials, ed 2.** New York: Thieme, 2008, pp 343–352
- Hadad G, Bassagasteguy L, Carrau RL, Mataza JC, Kassam A, Snyderman CH, et al: A novel reconstructive technique after endoscopic expanded endonasal approaches: vascular pedicle nasoseptal flap. **Laryngoscope** 116:1882–1886, 2006
- Hoffman HJ: Surgical management of craniopharyngioma. **Pediatr Neurosurg** 21 (Suppl 1):44–49, 1994
- Hofmann BM, Höllig A, Strauss C, Buslei R, Buchfelder M, Fahlbusch R: Results after treatment of craniopharyngiomas: further experiences with 73 patients since 1997. Clinical article. **J Neurosurg** 116:373–384, 2012
- Jane JA Jr, Kiehna E, Payne SC, Early SV, Laws ER Jr: Early outcomes of endoscopic transsphenoidal surgery for adult craniopharyngiomas. **Neurosurg Focus** 28(4):E9, 2010
- Kassam AB, Gardner PA, Snyderman CH, Carrau RL, Mintz AH, Prevedello DM: Expanded endonasal approach, a fully endoscopic transnasal approach for the resection of midline suprasellar craniopharyngiomas: a new classification based on the infundibulum. **J Neurosurg** 108:715–728, 2008
- Koc K, Anik I, Ozdamar D, Cabuk B, Keskin G, Ceylan S: The learning curve in endoscopic pituitary surgery and our experience. **Neurosurg Rev** 29:298–305, 2006 (Erratum in **Neurosurg Rev** 30:96, 2007)
- Koutourousiou M, Gardner PA, Fernandez-Miranda JC, Tyler-Kabara EC, Wang EW, Snyderman CH: Endoscopic endonasal surgery for craniopharyngiomas: surgical outcome in 64 patients. Clinical article. **J Neurosurg** 119:1194–1207, 2013
- Kulwin C, Schwartz TH, Cohen-Gadol AA: Endoscopic extended transsphenoidal resection of tuberculum sellae meningiomas: nuances of neurosurgical technique. **Neurosurg Focus** 35(6):E6, 2013
- Laufer I, Anand VK, Schwartz TH: Endoscopic, endonasal extended transsphenoidal, transplanum transtuberulum approach for resection of suprasellar lesions. **J Neurosurg** 106:400–406, 2007
- Leng LZ, Brown S, Anand VK, Schwartz TH: “Gasket-seal” watertight closure in minimal-access endoscopic cranial base surgery. **Neurosurgery** 62 (5 Suppl 2):ONSE342–ONSE343, 2008
- Leng LZ, Greenfield JP, Souweidane MM, Anand VK, Schwartz TH: Endoscopic, endonasal resection of craniopharyngiomas: analysis of outcome including extent of resection, cerebrospinal fluid leak, return to preoperative productivity, and body mass index. **Neurosurgery** 70:110–124, 2012
- Liu JK, Christiano LD, Patel SK, Eloy JA: Surgical nuances for removal of retrochiasmatic craniopharyngioma via the endoscopic endonasal extended transsphenoidal transplanum transtuberulum approach. **Neurosurg Focus** 30(4):E14, 2011
- Mascarenhas L, Moshel YA, Bayad F, Szentirmai O, Salek AA, Leng LZ, et al: The transplanum transtuberulum approaches for suprasellar and sellar-suprasellar lesions: avoidance of cerebrospinal fluid leak and lessons learned. **World Neurosurg** [epub ahead of print], 2013
- McCoul ED, Anand VK, Schwartz TH: Improvements in site-specific quality of life 6 months after endoscopic anterior skull base surgery: a prospective study. Clinical article. **J Neurosurg** 117:498–506, 2012
- McCoul ED, Anand VK, Singh A, Nyquist GG, Schaberg MR, Schwartz TH: Long-term effectiveness of a reconstructive protocol using the nasoseptal flap after endoscopic skull base surgery. **World Neurosurg** 81:136–143, 2014
- Minamida Y, Mikami T, Hashi K, Houkin K: Surgical management of the recurrence and regrowth of craniopharyngiomas. **J Neurosurg** 103:224–232, 2005
- Mortini P, Losa M, Pozzobon G, Barzaghi R, Riva M, Acerno S, et al: Neurosurgical treatment of craniopharyngioma in adults and children: early and long-term results in a large case series. Clinical article. **J Neurosurg** 114:1350–1359, 2011
- Nyquist GG, Anand VK, Brown S, Singh A, Tabaei A, Schwartz TH: Middle turbinate preservation in endoscopic transsphenoidal surgery of the anterior skull base. **Skull Base** 20:343–347, 2010
- Nyquist GG, Anand VK, Singh A, Schwartz TH: Janus flap: bilateral nasoseptal flaps for anterior skull base reconstruction. **Otolaryngol Head Neck Surg** 142:327–331, 2010
- O'Malley BW Jr, Grady MS, Gabel BC, Cohen MA, Heuer GG, Pisapia J, et al: Comparison of endoscopic and microscopic removal of pituitary adenomas: single-surgeon experience.

- rience and the learning curve. **Neurosurg Focus** **25**(6):E10, 2008
35. Oldfield EH: Editorial. Transnasal endoscopic surgery for craniopharyngiomas. **Neurosurg Focus** **28**(4):E8a, 2010
 36. Patel KS, Komotar RJ, Szentirmai O, Moussazadeh N, Raper DM, Starke RM, et al: Case-specific protocol to reduce cerebrospinal fluid leakage after endonasal endoscopic surgery. Clinical article. **J Neurosurg** **119**:661–668, 2013
 37. Placantonakis DG, Tabae A, Anand VK, Hiltzik D, Schwartz TH: Safety of low-dose intrathecal fluorescein in endoscopic cranial base surgery. **Neurosurgery** **61** (3 Suppl):161–166, 2007
 38. Sainte-Rose C, Puget S, Wray A, Zerah M, Grill J, Brauner R, et al: Craniopharyngioma: the pendulum of surgical management. **Childs Nerv Syst** **21**:691–695, 2005
 39. Silva D, Attia M, Kandasamy J, Alimi M, Anand VK, Schwartz TH: Endoscopic endonasal transsphenoidal “above and below” approach to the retroinfundibular area and interpeduncular cistern—cadaveric study and case illustrations. **World Neurosurg** **81**:374–384, 2014
 40. Smith SJ, Eralil G, Woon K, Sama A, Dow G, Robertson I: Light at the end of the tunnel: the learning curve associated with endoscopic transsphenoidal skull base surgery. **Skull Base** **20**:69–74, 2010
 41. Steno J, Maláček M, Bízik I: Tumor-third ventricular relationships in supradiaphragmatic craniopharyngiomas: correlation of morphological, magnetic resonance imaging, and operative findings. **Neurosurgery** **54**:1051–1060, 2004
 42. Wang KC, Kim SK, Choe G, Chi JG, Cho BK: Growth patterns of craniopharyngioma in children: role of the diaphragm sellae and its surgical implication. **Surg Neurol** **57**:25–33, 2002
 43. Zada G, Kelly DF, Cohan P, Wang C, Swerdloff R: Endonasal

transsphenoidal approach for pituitary adenomas and other sellar lesions: an assessment of efficacy, safety, and patient impressions. **J Neurosurg** **98**:350–358, 2003

Manuscript submitted June 17, 2014.

Accepted July 17, 2014.

Please include this information when citing this paper: DOI: 10.3171/2014.7.FOCUS14364.

Supplemental online information:

Video 1: http://mfile.akamai.com/21490/wmv/digitalwbc.download.akamai.com/21492/wm.digitalsource-na-regional/focus14-364_video_1.asx (Media Player).

http://mfile.akamai.com/21488/mov/digitalwbc.download.akamai.com/21492/qt.digitalsource-global/focus14-364_video_1.mov (Quicktime).

Video 2: http://mfile.akamai.com/21490/wmv/digitalwbc.download.akamai.com/21492/wm.digitalsource-na-regional/focus14-364_video_2.asx (Media Player).

http://mfile.akamai.com/21488/mov/digitalwbc.download.akamai.com/21492/qt.digitalsource-global/focus14-364_video_2.mov (Quicktime).

Video 3: http://mfile.akamai.com/21490/wmv/digitalwbc.download.akamai.com/21492/wm.digitalsource-na-regional/focus14-364_video_3.asx (Media Player).

http://mfile.akamai.com/21488/mov/digitalwbc.download.akamai.com/21492/qt.digitalsource-global/focus14-364_video_3.mov (Quicktime).

Address correspondence to: Aaron A. Cohen-Gadol, M.D., M.Sc., Department of Neurological Surgery, Goodman Campbell Brain and Spine, Indiana University School of Medicine, 355 W. 16th St., Ste. 5100, Indianapolis, IN 46202. email: acohenmd@gmail.com.